

Eliminating the Vertical Scar in Breast Reduction— Boston Modification of the Robertson Technique

Kiya Movassaghi, MD, DMD; Eric C. Liao, MD, PhD; Vivian Ting, MD; Evan Matros, MD; Donald J. Morris, MD; Dennis P. Orgill, MD, PhD; and Julian J. Pribaz, MD

From the Harvard Plastic Surgery Program, Brigham and Women's Hospital and Beth Israel Deaconess Medical Center; Harvard Medical School, Boston, MA.

Background: Surgeons often advise patients with large ptotic breasts to undergo a Wise pattern reduction (WPR) mammoplasty using an inferior pedicle technique with consideration of a free-nipple graft.

Objective: We describe the Boston modification of the Robertson technique (BMRT), which allows for the elimination of the vertical scar using a low horizontal scar mammoplasty with a broad central-inferior pedicle.

Methods: We retrospectively reviewed the surgical characteristics of 239 patients who underwent mammoplasty using the BMRT technique ($n = 145$) and compared these with patients undergoing WPR ($n = 94$). Patients were eligible for BMRT if they had a minimum of 5 cm between the lower aspect of the new areola and superior aspect of the old areola.

Results: The BMRT patients were more obese than the WPR patients ($BMI\ 32.4 \pm 6\ kg/m^2$ vs $28.0 \pm 5\ kg/m^2$) and also were more ptotic. The average distance from the suprasternal notch to the nipple was ($36.5 \pm 5\ cm$ vs $30.1 \pm 3\ cm$). For bilateral reductions, the average combined weight removed was 1240 g for BMRT, and 700 g for WPR. The BMRT unilateral reductions also had more tissue removed than unilateral WPRs (980 g vs 465 g). Rates of hematoma formation, minor wound dehiscence, and scar hypertrophy were greater in bilateral WPRs compared to bilateral BMRT mammoplasties.

Conclusions: The BMRT is a safe and reliable method of reduction mammoplasty when there is macromastia and significant ptosis. This technique avoids the vertical scar and hides the transverse scar in the shadow of the inferior breast. (Aesthetic Surg J 2006;26:687–696.)

The ideal reduction mammoplasty should produce a perfect breast size, shape, and projection with minimal scarring, normal nipple sensation, and ability to lactate. Ideally, it should also be easy and expeditious, free from complications, and reproducible by most surgeons.

Numerous reports have established the efficacy of inverted-T scar methods.¹⁻⁷ The disadvantages of these techniques, which include an extensive scar pattern, a propensity for hypertrophic scar formation, and poor long-term shape, have encouraged the development of alternative methods, such as vertical and transverse-scar reduction mammoplasties.⁸⁻²⁴ The vertical-scar techniques eliminate the transverse scar, but the current indications used by most surgeons limit them to patients with less ptosis who need smaller-volume reductions.¹⁶ For larger and more ptotic breasts, the Wise pattern mammoplasty (with or without free nipple grafting) is the most common technique. Multiple transverse scar techniques have been described as alternatives for this group of patients. These techniques eliminate the vertical scar.¹⁸⁻²⁴

In 1967, Robertson¹⁸ described a mammoplasty technique for very large breasts in which an inferior flap was shaped to produce a conical breast after the excision of a central transverse wedge of hypertrophied breast. The reduced breast had a bell-shaped transverse scar passing through its mid-axis with a free graft of the nipple-areola complex (NAC). In 1983, Hurst et al²⁰ presented the first modification of the inferior flap technique of Robertson in order to eliminate one of its main disadvantages—the need for nipple grafting (Figure 1). They preserved the nipple on a broad dermal inferior pedicle.

The senior author of this project (JJP) learned the modified Robertson technique while in training.²⁵ He later modified the technique to its current state in order to overcome the other main disadvantage of the original Robertson technique, which is a highly visible transverse bell-shaped scar through the mid-axis of the breast. This latest technique utilizes the same inferior pedicle principle, but adds a superior apron flap to conceal the transverse scar along the inferior portion of the breast. This paper describes our modification of the Robertson tech-

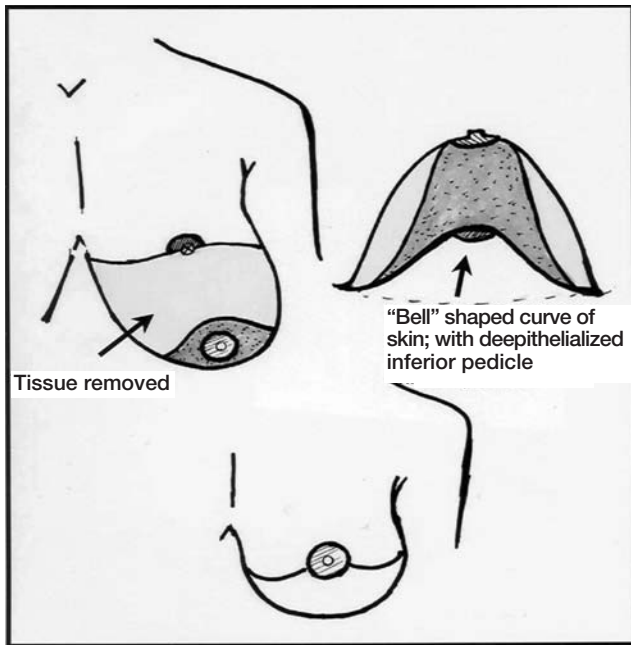


Figure 1. Initial modification of Robertson technique by Hurst et al,²⁰ which eliminated the need for nipple grafting as it was described by Robertson.¹⁸ Note the high placement of the transverse scar.

nique—the Boston modification (BMRT)—and reviews our results.

Methods

We retrospectively reviewed the charts of 145 patients who underwent breast reduction utilizing BMRT. These procedures were performed by 3 surgeons at 2 institutions (Brigham and Women's Hospital and Beth Israel Deaconess Medical Center) over a 6-year period from 1995 to 2001. Patients were selected for this technique if they had a minimum of 5 cm between the lower aspect of the new areola and superior aspect of the old areola. In this group, 116 patients underwent bilateral reduction mammoplasty (BMRT). The other 29 patients underwent unilateral breast reductions to match the size of a contralateral breast that previously underwent modified radical mastectomy with reconstruction (BMRT-u). The method of contralateral breast reconstruction included expander/implant as well as rectus abdominus and latissimus dorsi flaps, with or without implant.

As a control, we compared BMRT patients to patients who underwent either bilateral (WPR, N = 73) or unilateral (WPR-u, N = 21) WPR mammoplasties. For data analysis, only patients with complete charts were used. This included 61 patients in BMRT, 15 in BMRT-u, 51 in WPR and 15 patients in WPR-u. We compared age,

patient height and weight, body mass index (BMI), size of reduction, distance from nipple to suprasternal notch, and complication rates between BMRT and WPR. Statistical analyses were performed using the Pearson correlation, *t* test, and Fisher exact test where appropriate. All statistical tests were 2-sided with a *P* value $\leq .05$ considered significant.

Technique

The BMRT combines the concept of a central, horizontal breast resection, as described by Robertson (Figure 1), with an apron technique similar to that described by other authors.^{20,23,24} It employs a central resection with a bell-patterned inferior pedicle.

The distance from the suprasternal notch to each nipple was measured (Figures 2 and 3). The new nipple position was then determined based on the existing inframammary fold and transposed to the anterior surface of the breast on what would constitute the superior flap (Figure 2, A). A 42-mL cookie cutter was used to center the areola on the site of the new nipple (Figure 3, C). The lower edge of the superior or "apron" flap was marked at a distance 5 to 6 cm below the inferior aspect of the new areola. The inferior pedicle was then designed in a bell-shaped pattern, with a broad base that tapered out towards the medial and lateral ends of the breast, to recruit a wide blood supply for the nipple (Figure 2, B).

To facilitate the dissection, the breasts were injected with tumescent solution, which helped achieve hemostasis and expedited the procedure. The inferior pedicle was then deepithelialized to within 2 to 3 cm of the inframammary fold, leaving the original inframammary fold undisturbed. The superior flap was then incised and raised as a thin flap (1.5 cm thick) up to the level of the new nipple position (this is the "apron flap") (Figures 2, C and 3, F). No further undermining was performed when this point was reached; instead, the scalpel was used to cut straight down to the pectoral fascia. The entire central transverse wedge of intervening breast tissue located between the bell inferiorly and the level of the new nipple site superiorly was excised as a single solid breast unit, leaving a central pyramidal cone of breast tissue beneath the NAC (Figure 3, G). It is important to excise larger lateral and smaller medial wedges of the remaining superior portion of the breast to narrow the transverse base of the new breast. If this is not done, the breast will have a transversely elongated, unaesthetic "boxy" appearance. The superior "apron" flap was then brought down over the inferior pedicle and sutured in place 2 to 3 cm above the inframammary fold. A full

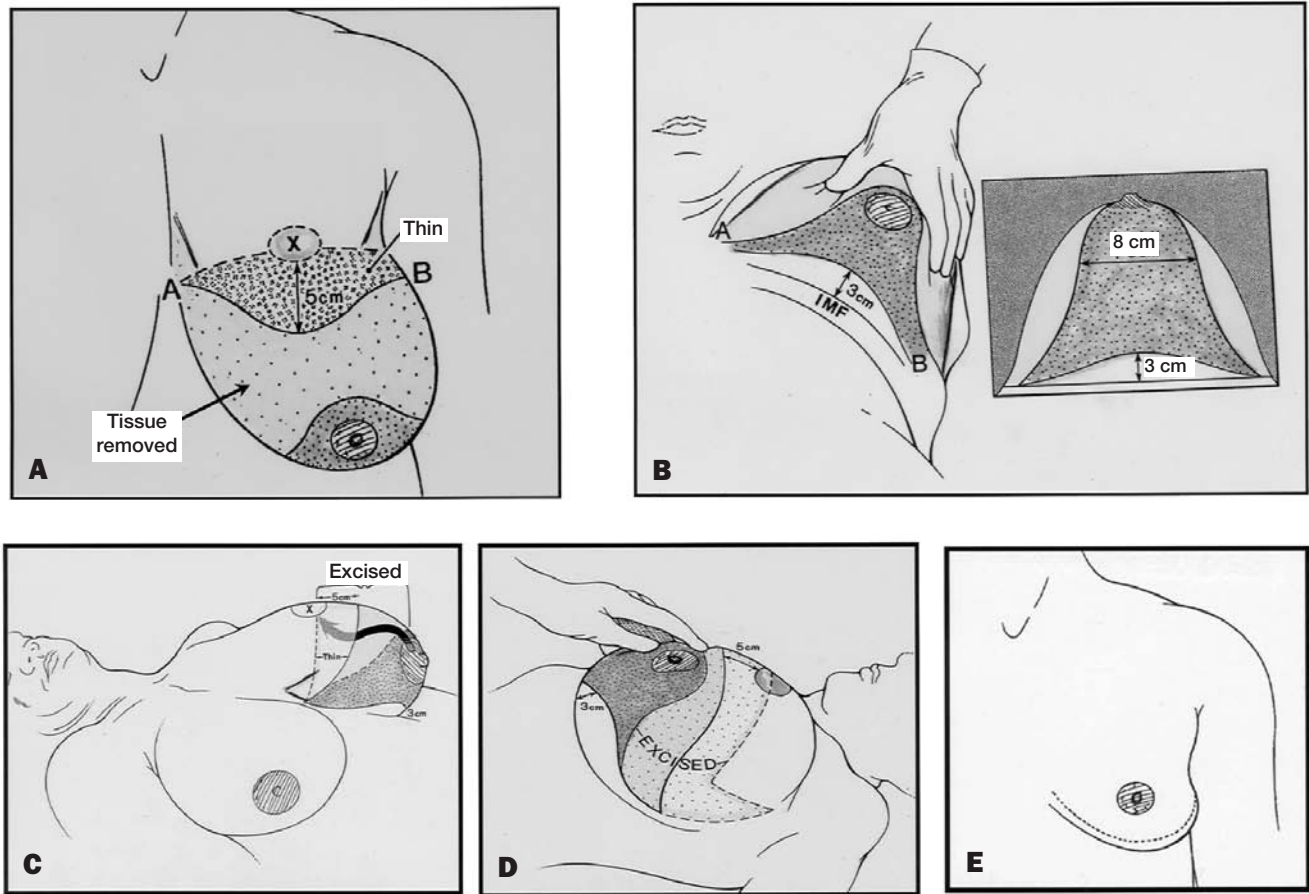


Figure 2. Design of the BMRT. **A**, Frontal view demonstrating the thin superior flap of 5 to 6 cm below the inferior edge of the new areola, the deepithelialized inferior pedicle, and the excised intervening breast tissue. **B**, Inferior view, showing the broad “bell-shaped” inferior pedicle, and no disturbance to inframammary fold. **C-E**, Medial and lateral view as well as the final location of scar. (Note the small medial and larger lateral triangular breast parenchyma that needs to be excised to narrow the transverse diameter of the breast and minimize the “boxy” appearance.)

thickness circle of skin and fat was excised from the superior flap at the site of the new nipple-areola, and the NAC complex was brought through to its new opening. This was sutured in circumferential fashion to the opening in the superior flap. The apron flap was sutured to the inferior incision, advancing any dog-ears toward the center of the incision (Figure 3, J).

If additional fullness laterally was present, lipoplasty was performed to debulk this area (Figure 3, H). Quilting sutures were used to obliterate the dead space laterally at the site of the lipoplasty and also at the site of the lateral wedge excision of excess breast tissue from the superior portion of the breast. This narrowed the transverse diameter of the breast and enhanced projection.

Results

Demographic data for the cohort of 142 patients with complete charts are shown in Table 1. Patients undergo-

ing either the BMRT or WPR had similar age distributions; however, patients undergoing unilateral mammoplasty were significantly older than those who underwent bilateral reductions ($P \leq .001$). This difference reflects the indication for surgery, since bilateral procedures were performed in younger patients with symptomatic macromastia, whereas unilateral procedures were completed in older patients diagnosed with cancer.

The BMRT patients were more obese than the WPR patients ($\text{BMI } 32 \pm 6 \text{ kg/m}^2$ vs $28 \pm 5 \text{ kg/m}^2$, $P \leq .001$). As described, BMRT was employed for breast reduction in patients with significant macromastia and breast ptosis. As expected, the BMRT reductions were larger than the WPRs in both the bilateral (1240 g vs 700 g, $P \leq .001$) and the unilateral (980 g vs 470 g; $P \leq .004$) groups. The degree of ptosis was also greater in bilateral BMRT reductions compared with bilateral WPRs (37 cm vs 30 cm, $P \leq .001$), but similar at 30 cm in both unilat-

Table 1. Summary of patient demographic and breast measurements*†

	Age	Height (in)	BMI (kg/m ²)	SN-N (cm)	Weight of breast excised per side (g)
BMRT (n = 61)	37 (±12)	64 (±3)	33 (±7)	37 (±5)	1240 (±510)
BMRT-u (n = 15)	55 (±9)	63 (±4)	31 (±6)	30 (±2)	980 (±610)
WPR (n = 51)	35 (±13)	64 (±3)	28 (±4)	30 (±2)	700 (±280)
WPR-u (n = 15)	51 (±8)	64 (±3)	29 (±6)	30 (±3)	470 (±310)

*For data analysis, only 142 patients with complete charts were used.

†Value listed is the mean, with SD noted in parentheses.

SN-N, distance from suprasternal notch to nipple.

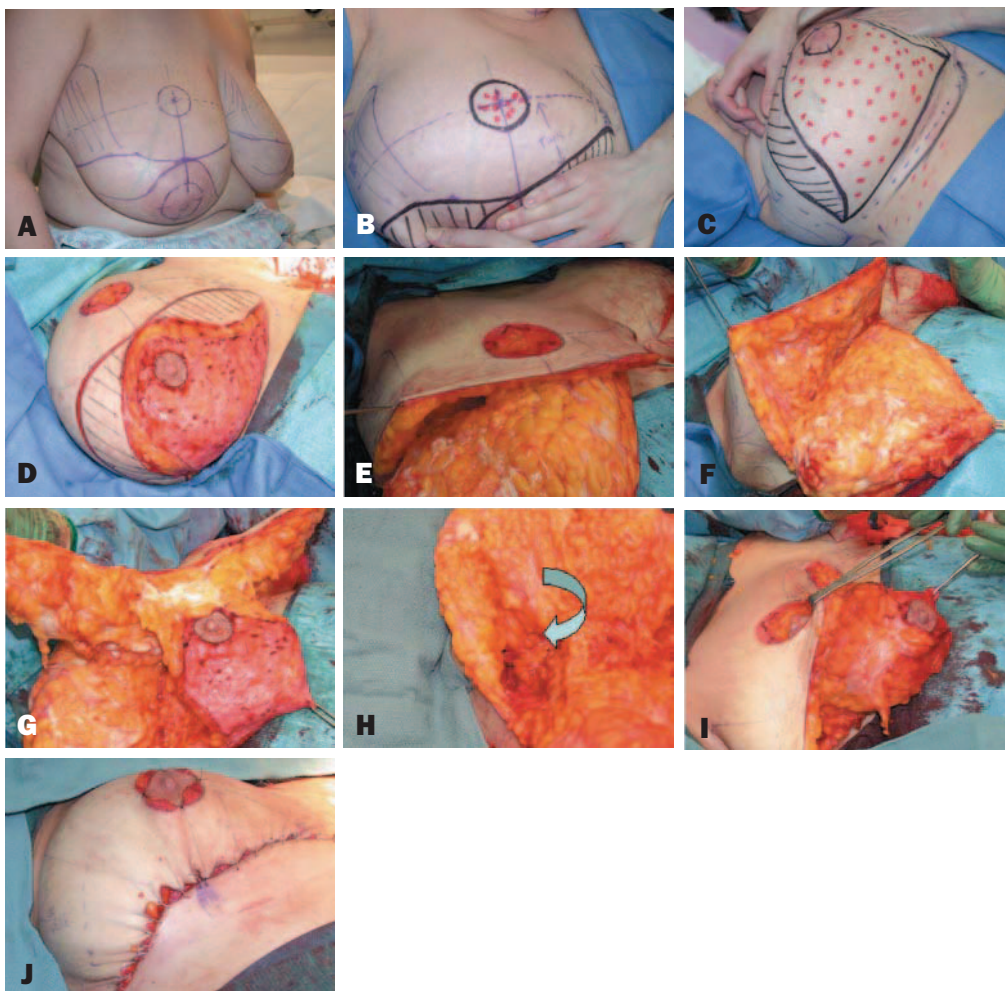


Figure 3. Operative technique. **A**, The new nipple site is marked along the mid-axis of the breast at the level of the inframammary fold. **B**, The thinner apron flap is marked 5 to 6 cm below the lower border of the new areola. Small medial and larger lateral wedge excisions are marked to narrow the transverse diameter of the breast. **C**, A bell-shaped curve based on the inframammary fold is marked with the nipple-areola complex at its apex. **D**, After injection of tumescent solution, the bell-shaped inferior pedicle is deepithelialized. **E, F**, The apron flap (1.5 cm thick) is undermined up to the mid-point of the new nipple site and the breast is incised vertically down to the pectoral fascia; there is no more superior undermining. **G**, The reduction is then performed removing a dumbbell-shaped transverse wedge of tissue. **H**, Additionally, large lateral and smaller medial wedges are excised for the superior flap. **I**, The residual broad-based pyramidal inferior pedicle is then brought up and the nipple-areola placed into its new location. **J**, The incision line is temporarily stapled closed, working in the redundancy of the longer upper flap centrally to minimize the dog ears. Final suturing is then completed.

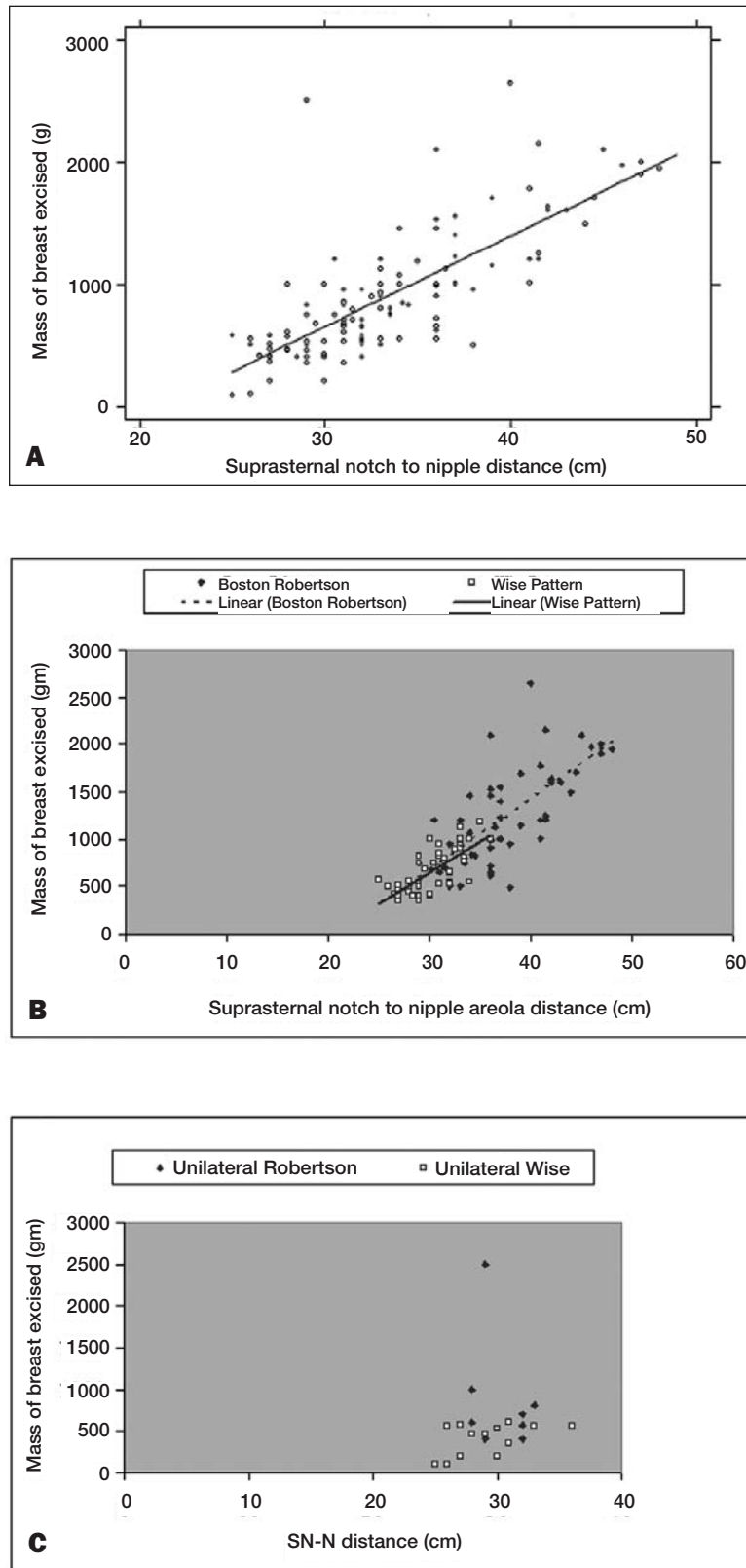


Figure 4. Relationship of mass of breast tissue excised to breast ptosis in BMRT and WPR mammoplasty. **A,** Graph of amount of breast tissue excised versus sternal notch distance. **B,** Scatter gram showing the data distribution as a plot of SN-N distance versus breast tissue excised in BMRT and WPR. **C,** Scatter gram showing the data distribution as a plot of SN-N distance versus breast tissue excised in BMRT-u and WPR-u.

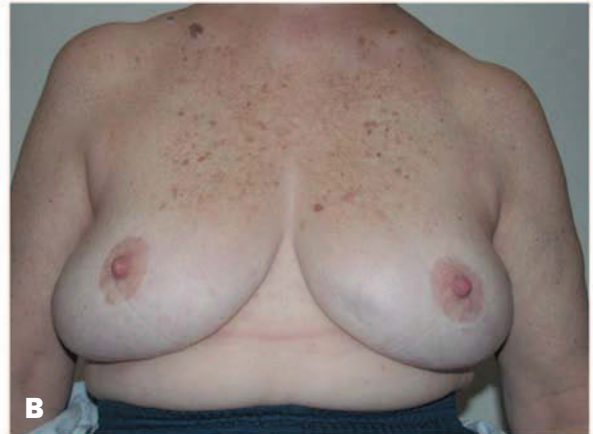
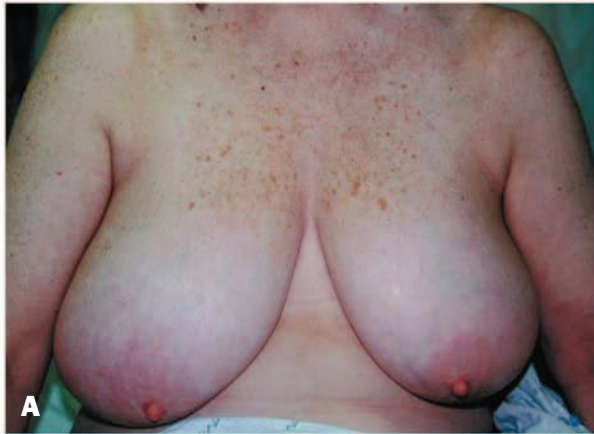
Figure 5. Ptosis and small reduction. **A,** Preoperative view of a 67-year-old woman. **B,** Postoperative view 7 years after removal of 650 g from the right breast and 500 g from the left breast.

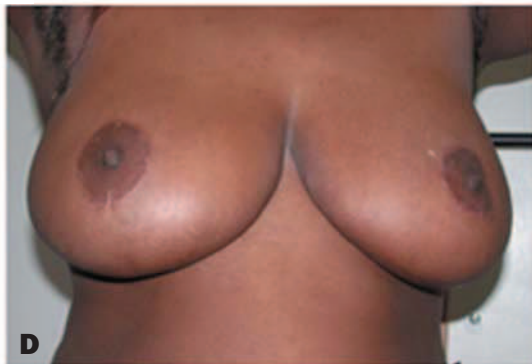
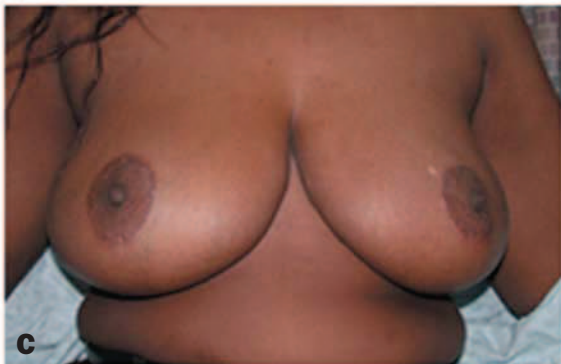
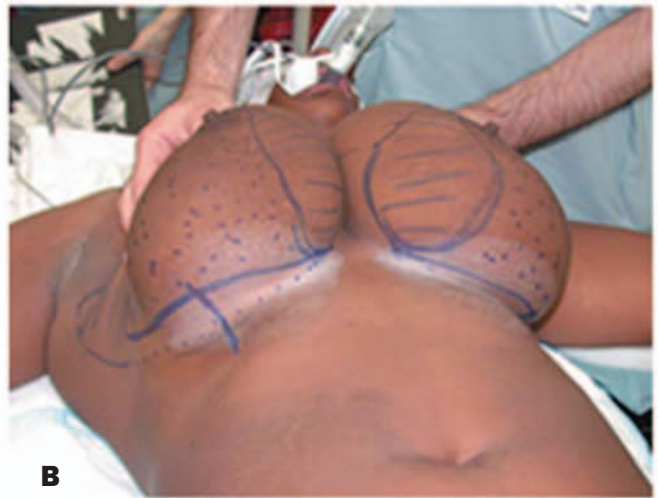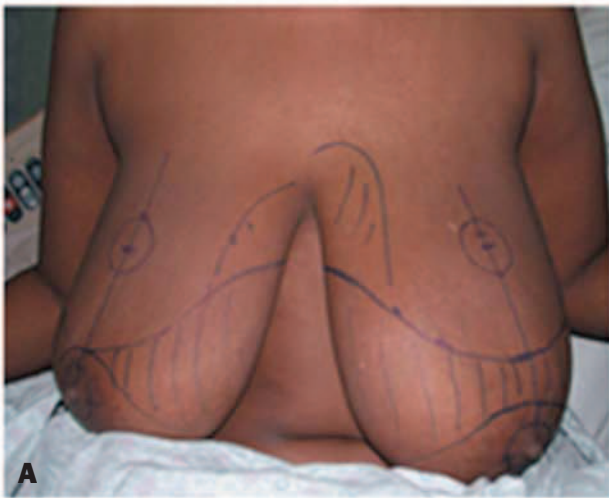Figure 6. Ptosis and moderately large reduction. **A, B,** Preoperative view of a 34-year-old woman with sternal notch-to-nipple distances of 35 and 37 inches. **C, D,** Postoperative views 6 months after removal of 1300 g from the right breast and 1800 g from the left breast.

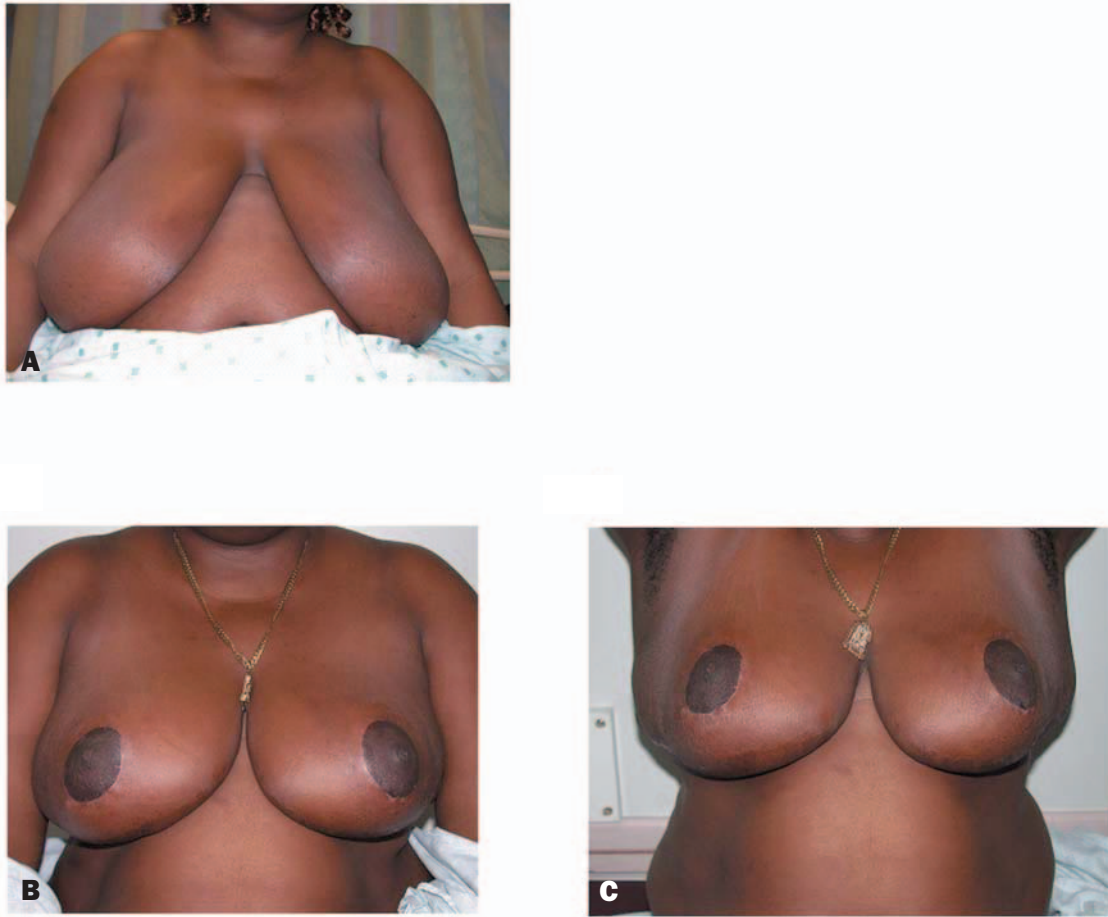


Figure 7. Ptosis and very large reduction. **A**, Preoperative view of a 24-year-old woman with a sternal notch-to-nipple distance of 50 cm. **B, C**, Postoperative views 8 weeks after removal of 2325 g from the right breast and 2355 g from the left breast.

eral reduction groups. A graph (Figure 4) of the amount of breast tissue excised versus sternal notch-to-nipple distance demonstrates a strong linear correlation between these parameters ($R = .776$, $P \leq .001$). This finding supports the utility of the sternal notch-to-nipple distance as a proxy for amount of tissue removed.

The average blood loss for BMRT was 300 mL with an average procedure length of 2 hours. However, when tumescence was used, the deepithelialization and resection could be done in 15 minutes or less, with bilateral reduction completed in 1.5 hours. Although no objective assessment of pseudoptosis was performed, there was no apparent pseudoptosis subjectively as is commonly observed with the T-scar technique. Representative cases of reduction mammoplasty utilizing BMRT are shown (Figures 5 to 8).

The average follow-up time was 8 months (range 1 month to 7 years) for BMRT, 12.9 months (range 2 to

48 months) for BMRT-u, and 6 months (range 4 to 8 months) for WPR and WPR-u. Complications including infection, minor wound dehiscence, hematoma formation, fat necrosis, scar hypertrophy, and nipple loss were compared between patients who underwent BMRT and WPR. As noted in Table 2, the rate of hematoma formation was significantly higher in WPR (10% vs 0%, $P \leq .016$). The rates of minor dehiscence and hypertrophic scar development were higher in WPR, but did not reach statistical significance. Most wound complications using the WPR technique occurred at the T-junction. Of note, there was no nipple loss in any patient. Two patients who underwent BMRT required scar revisions for removal of dog-ears laterally.

Discussion

The fact that there are many reported breast reduction techniques indicates that the ideal “for all seasons”

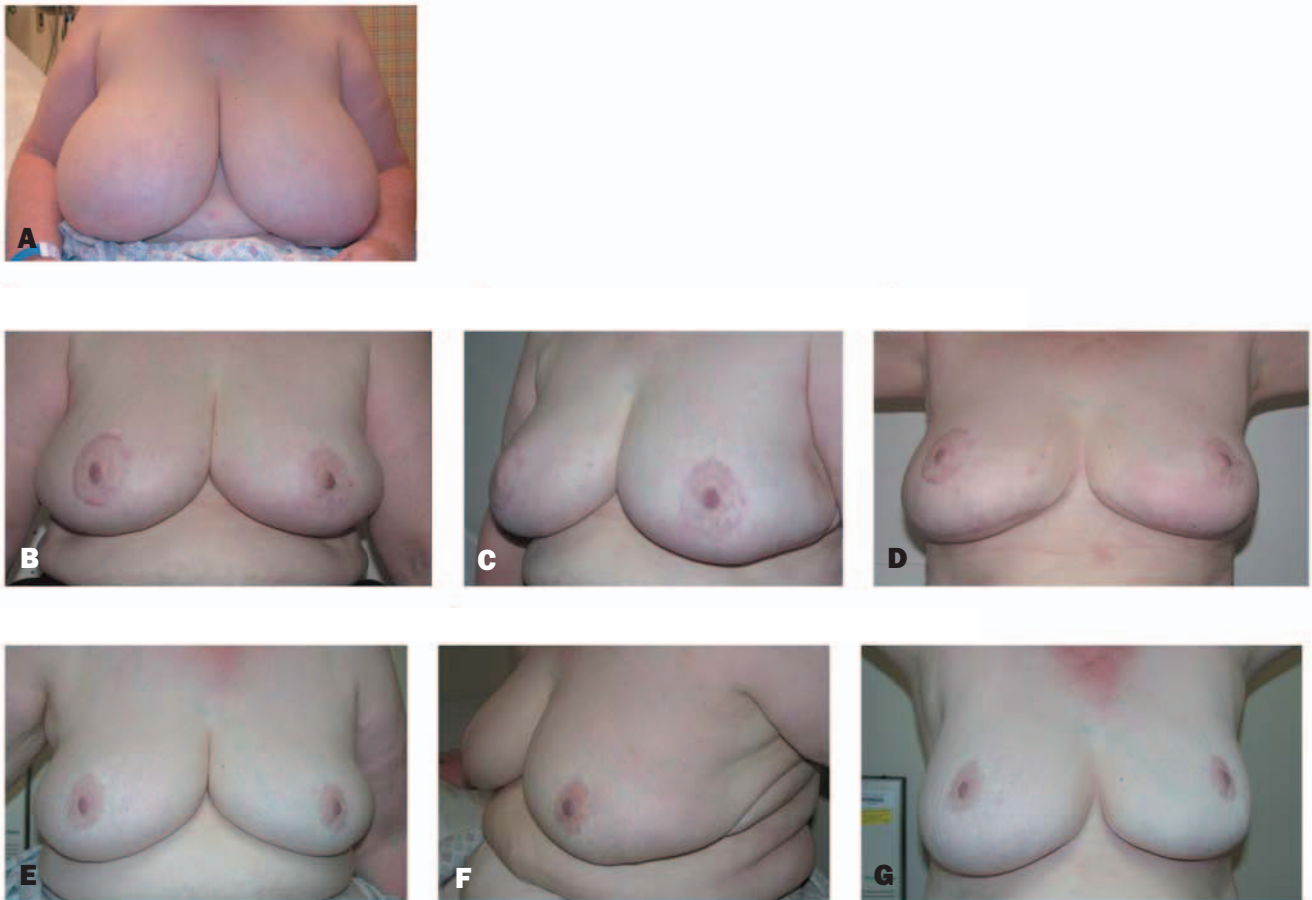


Figure 8. Ptosis and very large reduction, long-term follow-up. **A**, Preoperative view of a 53-year-old patient with a sternal notch-to-nipple distance of 42 cm. **B-D**, Postoperative views 12 months after removal of 1665 g from the right breast and 1815 g from the left breast. **E-G**, Three-year postoperative views. Note the preservation of overall breast shape in long-term follow-up.

Table 2. Summary of complications

	Infection	Minor dehiscence	Hematoma	Fat necrosis	Hypertrophic scars	Nipple loss
BMRT (n = 61)	2 (3%)	4 (6%)	0	3 (4.9%)	1 (2 %)	0
WPR (n = 51)	1 (2%)	9 (18.4%)	5 (10%)	3 (6.1%)	5 (12%)	0
P value*	NS	.075	.016	NS	.087	–

*Using 2-sided Fisher exact test.

breast reduction procedure remains elusive. This report parallels others in its quest for the ideal mammoplasty technique with the fewest scars. The inverted-T scar reduction methods remain the standard against which newer techniques are compared. To replace it, a new technique must achieve the same patient satisfaction rate, result in a superior and durable shape with fewer scars, and be easily reproducible and expeditious.

We find that BMRT fulfills most of these criteria. Once learned, it is fairly easy to perform, and the results are reproducible and free of major complications. In terms of breast size and shape, BMRT results have been superior to WPR. The immediate appearance of the breasts on the operating table, in the early postoperative period and long term, are very pleasing and natural. The BMRT has the same advantage as T-scar reduction, in that it uses a wide inferior pedicle to maintain nipple-areola circulation and provides a breast mound without need for nipple grafting. In contrast to the T-scar, BMRT uses a superiorly based flap (apron) that, once redraped and sutured to the lower incision 3 cm above the fold, provides a “skin brassiere” below the areola. The undisturbed dermis and breast tissue at and above the inframammary fold is believed to resist the stretching that the vertical scar in the T-scar reduction routinely undergoes. Also, the presence of an undisturbed inframammary fold is thought to be largely responsible for the prevention of pseudoptosis.²⁶

This technique works especially well in breast reduction cases where large mass excision is required and where marked ptosis exists. In our experience, BMRT mammoplasty can be performed rapidly and provides freedom in contouring the underlying breast. These advantages are even more pronounced when used in the reduction of very large breasts, where the larger mass and ptotic shape of the breasts often challenge the technique of the standard inverted-T design.

The safety of BMRT is evident when its complication rates are compared to an age-matched group of patients who have undergone WPR. Patients undergoing BMRT, despite being more obese with larger breasts than patients undergoing WPR, had either similar or significantly lower complications rates than the WPR patients. There was no incidence of nipple necrosis. In unilateral reductions for symmetry after breast cancer, we used BMRT on women with a suprasternal notch-to-nipple distance that was less than average for bilateral reductions. This was an older group that tended to have less breast mass removed, had relatively more ptosis relative to macromastia, and often

had less of an areolar diameter than some of the younger patients with more breast hypertrophy.

Chalekson et al²⁶ recently showed that the modified Robertson technique as described by Hurst et al²⁰ does not lead to pseudoptosis, which is commonly associated with WPR. Subjectively, we have also observed minimal to no pseudoptosis with BMRT, although this requires further clarification by recording accurate measurements before and after the operation. Currently, a prospective study to assess this is under way.

One disadvantage of BMRT is the occasional need for the lateral extension of the transverse scar in obese patients with fat rolls extending into the back. Also, if lateral and medial wedge excisions of the breast parenchyma are not done adequately, the breasts can have a “boxy” appearance.

Conclusion

The BMRT is a reliable technique in reduction mammoplasty when macromastia and significant ptosis are present. It has the added benefits of avoiding the vertical scar, hiding the transverse scar in the shadow of the inferior breast, potentially avoiding or minimizing pseudoptosis, and being an expeditious treatment. ■

References

1. McKissock PK. Reduction mammoplasty with a vertical dermal flap. *Plast Reconstr Surg* 1972;49:245-252.
2. Courtiss EH, Goldwyn RM. Reduction mammoplasty by the inferior pedicle technique. *Plast Reconstr Surg* 1977;59:500-507.
3. Robbins TH. A reduction mammoplasty with the areola-nipple based on an inferior dermal pedicle. *Plast Reconstr Surg* 1977;59:64-67.
4. Hester TR, Bostwick J, Miller L, et al. Breast reduction utilizing the maximally vascularized central breast pedicle. *Plast Reconstr Surg* 1985;76:890-900.
5. Hugo NE, McClellan RM. Reduction mammoplasty with a single superiorly based based pedicle. *Plast Reconstr Surg* 1979;63:230-234.
6. Georgiade NG, Serafin D, Morris R, et al. Reduction mammoplasty utilizing an inferior pedicle nipple-areolar flap. *Ann Plast Surg* 1979;23:211-218.
7. Mathes SJ, Nahai F, Hester TR. Avoiding the flat breast in reduction mammoplasty. *Plast Reconstr Surg* 1980;66:63-70.
8. Reus WF, Mathes SJ. Preservation of projection after reduction mammoplasty: long-term follow-up of the inferior pedicle technique. *Plast Reconstr Surg* 1988;82:644-652.
9. Orlando JC, Guthrie RH. The superomedial dermal pedicle for nipple transposition. *Br J Plast Surg* 1975;28:42-45.
10. Lassus CA. 30-year experience with vertical mammoplasty. *Plast Reconstr Surg* 1996;97:373-380.
11. Lassus C. Breast reduction: evolution of a technique—a single vertical scar. *Aesthetic Plast Surg* 1987;11:107-112.
12. Lejour M. Vertical mammoplasty and liposuction of the breast. *Plast Reconstr Surg* 1994;94:100-114.
13. Benelli LA. new periareolar mammoplasty: the “round block” technique. *Aesthetic Plast Surg* 1990;14:93-100.

14. Hidalgo D, Hirmand H. Deaugmentation reduction mammoplasty. *Aesthetic Surg J* 2004;24:112-116.
15. Coehlo de Almeida CI. Mammoplasty with L-incision. *Aesthetic Surg J* 2004;24:102-111.
16. Hidalgo DA, Elliot LF, Palumbo S, et al. Current trends in breast reduction. *Plast Reconstr Surg* 1999;104:806-815.
17. Hall-Findlay EJ. Vertical breast reduction: a critical analysis of 400 cases. *Plast Surg Forum* 1998; 21:133.
18. Robertson DC. The technique of inferior flap mammoplasty. *Plast Reconstr Surg* 1967;40:372-377.
19. Bretteville-Jensen G. Reduction mammoplasty with a vertical bipedicle and transverse scar: a follow-up. *Br J Plast Surg* 1976;29:142-149.
20. Hurst LN, Evans HB, Murray KA. Inferior flap reduction mammoplasty with pedicle nipple. *Ann Plast Surg* 1983;10:483-485.
21. Arons MS. The reduction of very large breasts: the inferior flap technique of Robertson. *Br J Plast Surg* 1976;29:137-141.
22. Yousif NJ, Larson DL, Sanger JR, Matloub HS. Elimination of the vertical scar in reduction mammoplasty. *Plast Reconstr Surg* 1992;89:459-467.
23. Lalonde DH, Lalonde J, French R. The no vertical scar breast reduction: a minor variation that allows you to remove vertical scar portion of the inferior pedicle wise pattern t scar. *Aesthetic Plast Surg* 2003;27:335-344.
24. Ribeiro L. A new technique for reduction mammoplasty. *Plast Reconstr Surg* 1975;55:330-334.
25. Morris DJ, Pribaz JJ, Abboud J. The modified Robertson breast reduction: revisited and revised. In: Proceedings of the 36th Annual of the New England Society of Plastic and Reconstructive Surgeons. Boston, Mass., 1995.
26. Chalekson CP, Neumeister MW, Zook EG, Russell RC. Outcome analysis of reduction mammoplasty using the modified Robertson technique. *Plast Reconstr Surg* 2002;110:71-79; discussion 80-81.

Accepted for publication August 18, 2006.

Reprint requests: Julian J. Pribaz, MD, Brigham and Women's Hospital, Division of Plastic Surgery, 75 Francis Street, Boston, MA 02115.

Copyright © 2006 by The American Society for Aesthetic Plastic Surgery, Inc.

1090-820X/\$32.00

doi:10.1016/j.asj.2006.10.010